

CLINICAL PRACTICE

Caren G. Solomon, M.D., M.P.H., *Editor*

Physical Abuse of Children

Carol D. Berkowitz, M.D.

This Journal feature begins with a case vignette highlighting a common clinical problem. Evidence supporting various strategies is then presented, followed by a review of formal guidelines, when they exist. The article ends with the author's clinical recommendations.

A 4-month-old male infant is brought to the emergency department by paramedics. His mother had dialed 911 because the infant appeared to be limp when she lifted him from his crib after she returned from work; she had left him with her boyfriend while she was at work. On arrival in the emergency department, the infant's temperature is 37°C, heart rate 114 beats per minute, blood pressure 90/68 mm Hg, and respiratory rate 28 breaths per minute. The physical examination is normal except for decreased muscle tone, and there is a 1-cm bruise on his left cheek. How should this case be evaluated and managed?

THE CLINICAL PROBLEM

SINCE THE PUBLICATION OF "THE BATTERED-CHILD SYNDROME" IN 1962,¹ which focused on the physical findings of child abuse, the concept of child maltreatment has expanded to include sexual abuse, emotional abuse, and neglect. Statistics on child maltreatment have been collected since 1988 as a result of an amendment to the Child Abuse Prevention and Treatment Act, which established the National Child Abuse and Neglect Data System. Although figures vary yearly, approximately 700,000 cases of child abuse and neglect are reported annually in the United States.² Figure 1 shows the number of cases of child abuse, according to the type of abuse, that were documented by the Department of Health and Human Services in 2015. This article focuses exclusively on physical abuse.

Assessments of child abuse involve the interaction of multiple disciplines, including medicine, social work, law enforcement, and the judicial system. This interdisciplinary approach, which is facilitated by Child Advocacy Centers or similar multidisciplinary models, can be challenging because of differing definitions of child abuse, expectations regarding information that can be determined during the medical evaluation, or interpretations of findings. Evidence as used in the context of "evidence-based medicine" differs in concept and methodology from evidence as used in the legal context. The physician may be asked to render a legal opinion as to whether medical findings indicate abuse; many published reports on medical findings indicative of abuse are based on observational data — primarily from case series — and on clinical judgment. Mechanical models that are used to simulate falls or shaking may not be applicable to children.^{3,4} In addition to a medical evaluation to guide treatment, findings that do not require therapy but that support an inflicted cause must also be documented. The legal mandate for physicians to report suspected child abuse requires a reasonable suspicion of abuse, which is sometimes a difficult criterion to meet because of uncertainty regarding

From the Harbor–UCLA Medical Center, David Geffen School of Medicine at UCLA, Torrance, CA. Address reprint requests to Dr. Berkowitz at the Department of Pediatrics, Harbor–UCLA Medical Center, 1000 W. Carson St., Torrance, CA 90509, or at cberkowitz52@gmail.com.

N Engl J Med 2017;376:1659-66.

DOI: 10.1056/NEJMc1701446

Copyright © 2017 Massachusetts Medical Society.



An audio version of this article is available at NEJM.org

KEY CLINICAL POINTS

PHYSICAL ABUSE OF CHILDREN

- Physically abused children, particularly infants, may present with nonspecific symptoms and signs, such as vomiting or apnea; the possibility of abusive head trauma requires consideration in such cases.
- Physical findings, such as bruising of the face, neck, or torso, or intraoral lesions, such as torn frenula, in infants who are not yet ambulatory should arouse suspicion of inflicted trauma.
- The evaluation of infants and young children for suspected inflicted trauma should include a complete physical examination of the child, with particular attention to the skin, oral cavity, and abdomen; imaging of the brain; a fundoscopic examination for retinal hemorrhages; a skeletal survey; and measurement of hepatic and pancreatic enzymes.
- Physicians are mandated to report to child protective services cases in which they have a reasonable suspicion of child abuse.

the diagnosis, particularly when the physician has an ongoing relationship with the family, in which case the physician may want to be more certain of the diagnosis.⁵

STRATEGIES AND EVIDENCE

EVALUATION

Although abused children may often have injuries to more than one area, some have injuries that are isolated or sentinel (i.e., having the potential to predict a catastrophic event). The recognition of such findings provides an opportunity for intervention and prevention of more serious consequences, including death. In addition to per-

forming a careful physical examination, assessors must be knowledgeable about child development and should assess the credibility of the details of the alleged event. Table 1 provides a list of the recommended steps that should be taken to assess cases of suspected child abuse. For the purpose of a brief overview of physical abuse, it is useful to categorize injuries into four domains: abusive head trauma, abdominal trauma, cutaneous and intraoral findings, and fractures.

ABUSIVE HEAD TRAUMA

The term “shaken-baby syndrome” was introduced more than 30 years ago,⁶ and since then, vigorous discussion has ensued regarding whether the neuropathologic symptoms associated with the shaken-baby syndrome are attributable to shaking alone or whether a blunt impact is required. In a 2009 policy statement, the American Academy of Pediatrics recommended replacing the term shaken-baby syndrome with “abusive head trauma” to avoid the connotation that the mechanism of injury was specifically known for individual cases⁷; we use the more recent terminology here.

The incidence of abusive head trauma is estimated at 20 to 30 cases per 100,000 infants younger than 1 year of age.⁸ Mild cases may go unrecognized, and fatal cases with additional injuries may be categorized as multiple traumatic injuries. Data indicate a decline in abusive head trauma during the period from 2009 through 2014.⁹ Infants and young children are at particular risk. Affected infants may have nonspecific symptoms or signs, such as a brief unexplained event that has resolved, apnea, altered mental status, loss of consciousness, limpness, vomiting, seizure, poor feeding, or swelling of the scalp.

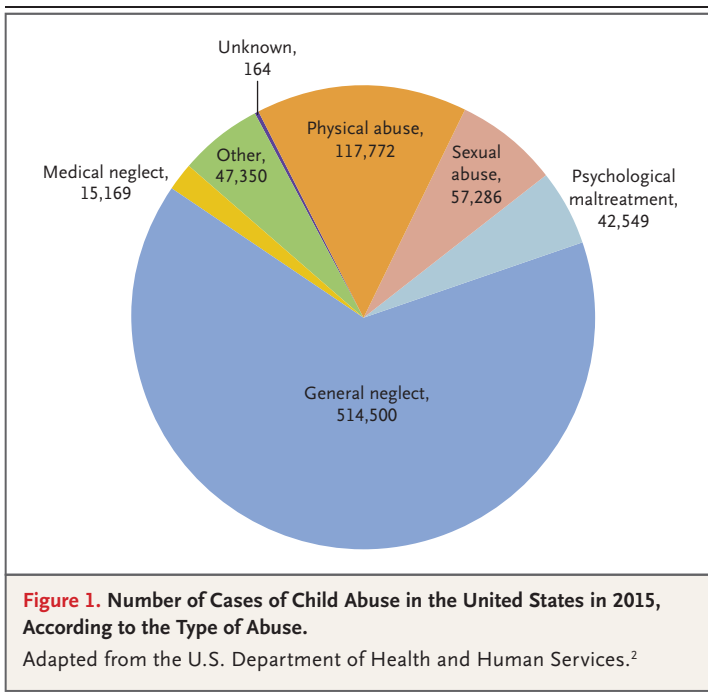


Table 1. Assessment for Suspected Physical Abuse of a Child.**Step 1: Obtain a careful history of the alleged circumstances surrounding the injury.**

- Were there witnesses to the event?
- Who was present with the child when the event occurred?
- Can the alleged event account for the injuries?
- Is the child's developmental level consistent with the proposed mechanism of injury?
- What was done when the event occurred or the child became symptomatic?
- Was there a delay in seeking medical attention?

Step 2: Perform a complete examination with the child fully unclothed.

- Document the overall clinical status of the child.
- Document the presence of any bruises, burns, or other cutaneous findings.
- Document the presence of intraoral lesions by carefully checking each frenulum for injury.
- Document the presence of findings such as subconjunctival hemorrhages.
- Photograph the findings or request that law enforcement obtain photographs.

Step 3: Initiate a diagnostic workup on the basis of the findings and clinical condition of the child. The acuteness of the child's condition and the need for medical intervention may determine the order in which diagnostic studies are obtained.

- Perform CT or MRI of the head.
- Perform CT of the abdomen with contrast enhancement if abdominal injuries are suspected.
- Obtain complete blood count, assess basic metabolic profile, perform coagulation studies, and measure hepatic and pancreatic enzymes.
- Perform a full skeletal survey.
- Perform a funduscopic examination with photographs.

Step 4: Manage any acute medical problem.**Step 5: Notify child protective services as mandated in the state. Notification of law enforcement is also mandated in some jurisdictions.****Step 6: Hospitalize the child if needed.****Step 7: Have hospital personnel or a child protective services social worker perform an extensive social evaluation.****Step 8: Consider an additional forensic workup if indicated or requested or refer the case to a pediatrician, team, or center that specializes in child abuse cases. Additional tests that might be performed include the following:**

- A radionuclide scan to look for occult or acute fractures
- A repeat skeletal survey in 2 weeks
- Evaluation for blood dyscrasia
- Evaluation for osteogenesis imperfecta
- Evaluation of other medical problems as suggested by the differential diagnosis of the findings

In the absence of another reasonable explanation, these clinical features should prompt consideration of abusive head trauma. In one report, a third of infants in whom abusive head trauma was subsequently diagnosed had been seen by a physician within 3 weeks before their diagnosis for nonspecific symptoms; at these earlier evaluations, abusive head trauma was not considered in the differential diagnosis.¹⁰ In another study of shaking in which perpetrators admitted to shaking a child, more than a quarter of infants

had previously presented with poor weight gain, ecchymoses, and fractures, conditions that were also diagnosed without suspicion of inflicted trauma as the cause.¹¹

The assessment of an infant for suspected abusive head trauma should include a thorough evaluation of the skin for bruising, especially the skin of the face, ear, neck, and torso, and an evaluation of the oral cavity (e.g., for a torn frenulum, which might be caused from efforts to silence a crying infant).¹² A funduscopic examina-

tion should be performed by a pediatric ophthalmologist, and when abnormal, photographs should be obtained to document the presence and extent of retinal hemorrhages, although retinal hemorrhages in the absence of intracranial injury are uncommon.^{13,14} Although the differential diagnosis of retinal hemorrhages is extensive, conditions such as leukemia, meningitis, and hypertension can be readily diagnosed by medical testing to distinguish the findings from those associated with physical abuse. The mechanism of retinal hemorrhages is related to traction on the retina by the vitreous as the eye moves back and forth within the orbit. Retinal hemorrhages are reported in approximately 85% of children with abusive head trauma. Extensive hemorrhages involve all layers of the retina, extend to the ora serrata, and may lead to retinal tears, schisis (abnormal splitting of the retina), retinal detachment, or vitreal hemorrhage. Skeletal surveys are also recommended.¹⁵ Among infants with abusive head trauma, associated rib fractures from forceful thoracic compression as the infant is held and shaken or fractures of the metaphyseal areas of the legs as the legs jerk back and forth during the shaking episode may also be present.¹⁶

Imaging of the brain and skull may show a range of findings.¹⁵ Computed tomography (CT) is recommended if acute neurologic symptoms or signs are present; otherwise, magnetic resonance imaging (MRI) is preferred to avoid the use of radiation, despite the need for sedation in the noncomatose child.¹⁷ Subdural hemorrhages may be noted but generally do not account for severe neurologic sequelae of head trauma (Fig. 2). Brain parenchyma may show a contusion or shear injury (i.e., diffuse axonal injury).¹⁸ Cerebral edema may be related to trauma or hypoxemia caused by apnea from brain-stem dysfunction (Fig. 3). MRI may reveal extraaxial hemorrhages of various ages that are indicative of previous injuries.¹¹ Skull fractures may be noted on the skeletal survey or the CT scan. Three-dimensional reconstruction of the bone windows (i.e., CT cross sections of the skull) helps to delineate areas of impact to the skull and differentiates cranial sutures from fractures.¹⁹

Parents may profess no explanation for the findings of head trauma; they may state that the baby was fine when placed in the crib, or they may suggest actions by the infant that are beyond the infant's developmental abilities. Some parents

may report a short fall (less than 1.5 m) as the reason for the child's severe intracranial injury. However, short falls are extremely unlikely to cause severe intracranial trauma; the estimated likelihood of death from such falls is 0.48 cases per 1 million children younger than 5 years of age.²⁰ A model that evaluated data from more than 1000 children who were younger than 3 years of age and had intracranial injury estimated the probability that the injury was related to abusive head trauma on the basis of the presence of six findings: apnea; retinal hemorrhages; rib fractures; long-bone fractures; seizures; and head bruising, neck bruising, or both.²¹ The positive predictive value for abusive head trauma varied from 4% if none of the factors were present to 97% if all six factors were present. Such data have been used to develop clinical prediction rules and to explain the significance of findings to investigators who do not have a medical background.²²

ABDOMINAL TRAUMA

Isolated inflicted abdominal trauma, although less common than head trauma across all age groups, affects older toddlers (median age, 2.6 years) more often than younger infants and carries a high risk of death because medical care may be delayed or symptoms misdiagnosed.²³ The most

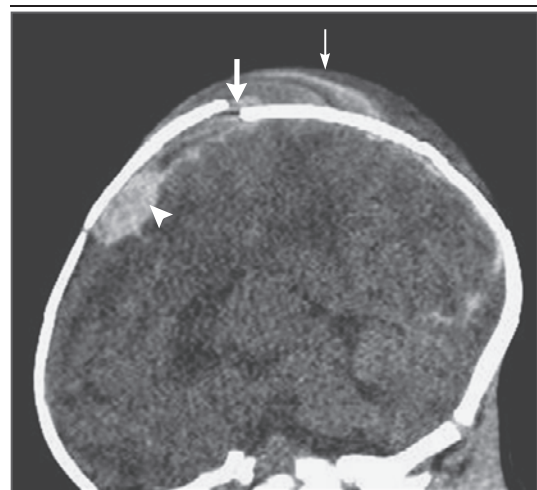


Figure 2. CT Scan of the Head of a 17-Day-Old Infant with a History of Fussiness.

A CT scan (sagittal view) of the head of a 17-day-old infant with a history of fussiness shows the presence of a skull fracture (thick arrow), cephalohematoma (thin arrow), and subdural hematoma (arrowhead).

common injuries include laceration or hematoma of the liver, splenic injury, hollow viscus injury or pancreatic injury, and hematoma of the duodenum.²³⁻²⁵

For proper examination, the child must be fully undressed. A bruise on the abdomen arouses concern for trauma; however, such bruises are uncommon because the force of a blow to the abdomen is dissipated internally and the skin is spared.

Because children with abusive head trauma may have occult abdominal injuries, the levels of hepatic and pancreatic enzymes should be measured in cases in which abusive head trauma is recognized or suspected.²⁴ Studies have shown that 3 to 4% of children who are evaluated for child abuse for any reason have elevated hepatic or pancreatic enzymes.^{24,26} Children with gastrointestinal symptoms, abdominal pain, or elevated enzymes should be evaluated by CT with intravenous administration of contrast material. Ultrasonography, which is sometimes performed when suspicion of abdominal trauma is low, is considerably less sensitive than CT.¹⁵

CUTANEOUS AND INTRAORAL FINDINGS

Bruises are common in young, mobile children and do not necessarily indicate inflicted injury.²⁷ Medical conditions, such as coagulopathies or certain genetic disorders, can confer a predisposition to “easy bruisability,” and screening for these disorders is recommended in a child who has extensive or atypical bruising. Falls often cause bruises over bony prominences (shins and forehead) but are less likely to cause bruising over areas such as the buttocks, hands, and trunk. In addition, a pediatric adage, “Those who don’t cruise rarely bruise,”²⁸ denotes that bruises, especially on the face or trunk, rarely occur in non-ambulatory infants. Bruises in these areas, as well as intraoral lesions, should be considered to be sentinel findings that arouse suspicion of inflicted injury.^{29,30} Patterned bruises that mirror an offending object, such as a handprint or belt mark, are also indicative of an inflicted injury. Inflicted burns from immersion in scalding water or from contact with a heated object may also have a characteristic appearance. Previously, bruises were assigned an estimated age on the basis of their color, but subsequent studies have shown substantial variation in the color and duration of bruises on the basis of the patient’s

age, the location of the bruise, and the extent or depth of the bruise.³¹

FRACTURES

Skeletal surveys are recommended in all children 2 years of age or younger in whom abuse is suspected (whether a fracture is specifically suspected or not) as well as in children older than 2 years of age in whom a fracture is present and an inflicted injury is suspected.¹⁵ Recommended radiographs include those of the skull (anteroposterior and lateral views); cervical, thoracic, and lumbosacral spine (anteroposterior and lateral views); ribs, including oblique views; bony pelvis (anteroposterior view); humeri (anteroposterior view), femora (anteroposterior view), and tibias (anteroposterior view); and hands (frontal view) and feet (anteroposterior view). In contrast to fractures in normally active children, fractures in children who are nonambulatory arouse concern for inflicted trauma, as do certain types of fractures.^{32,33} Both rib fractures and classic metaphyseal lesions (“chip” fractures or “bucket handle” fractures) are considered to be fairly specific for inflicted injuries.^{16,34,35}

Fractures that result from squeezing an infant usually involve the lateral or posterior aspects of

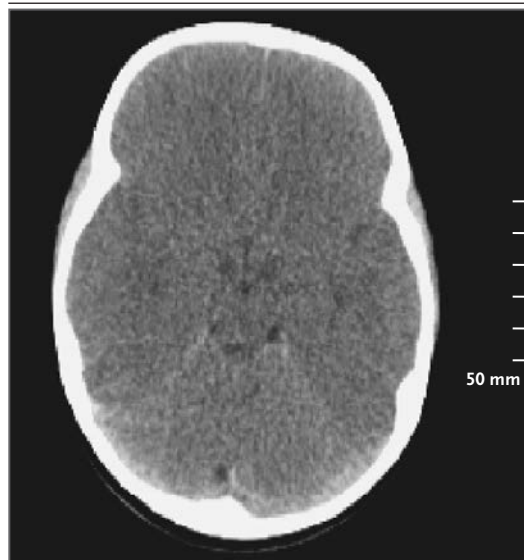


Figure 3. CT Scan of the Head of a 30-Month-Old Toddler with a History of Falling from a Standing Position.

Cerebral edema and loss of gray-white differentiation can be seen in this CT scan of the head of a 30-month-old toddler with a history of falling to the floor from a standing position.

the ribs. Acute rib fractures are difficult to see on a standard radiograph but may be seen on a nuclear bone scan. Alternatively, when initial images of the ribs appear to be negative, a repeat radiograph 2 weeks later may reveal callus formation. During this 2-week period, depending on other findings, the child may be hospitalized or may reside in the family home or in a foster home. A repeat skeletal survey is a routine part of the forensic evaluation, even in cases in which a newly detected fracture does not require therapeutic intervention.³⁶

The precise mechanism by which metaphyseal lesions occur is unclear but may involve a sudden tug or a shear to the ends of the bones.³⁴ Callus formation is not apparent, and lesions appear as metaphyseal chips or irregularities. Radiographic findings may resemble metaphyseal changes related to rickets or congenital infections; distinguishing among these conditions, with the use of other clinical and laboratory findings, is important to avoid misdiagnosis. Fractures involving the scapula, sternum, or acromion are less common but are of similar concern. Although fractures such as spiral fractures of long bones may be inflicted, such fractures also occur accidentally (e.g., “toddler’s fracture” [distal spiral tibial fracture]). In the assessment of any fracture, the proposed mechanism of injury and the developmental ability of the child need to be considered.

Other causes of fracture warrant consideration. Although there is evidence that adults with vitamin D insufficiency are at increased risk for fractures, studies have not shown a higher prevalence of fractures among children with low vitamin D levels in the absence of biochemical or radiologic evidence of rickets.³⁷⁻³⁹ Administration of vitamin D is now recommended for all breast-fed infants to prevent rickets.

Osteogenesis imperfecta should be considered in any child who has multiple fractures.⁴⁰ At least eight different types of osteogenesis imperfecta have been identified. Physical findings (e.g., blue sclerae or wormian bones [i.e., irregular bone that is present within cranial sutures]) or a family history of the condition may suggest the diagnosis. When genetic testing for *COL1A1* and *COL1A2* (mutations of which are associated with osteogenesis imperfecta) uncovers a variant of unknown significance, the relationship to osteogenesis imperfecta is uncertain; therefore, genetic

consultation is warranted when further evaluation of the fractures is considered. Courts may request diagnostic studies, even in cases in which medical indications are absent.

AREAS OF UNCERTAINTY

Uncertainties continue to surround determinations of abusive head trauma. Whether an impact is needed to cause brain injury or whether the injury can be sustained with shaking alone is still under debate. According to the American Academy of Pediatrics, “The act of shaking leading to shaken baby syndrome is so violent that individuals observing it would recognize it as dangerous and likely to kill a child.”⁴¹ The “unified hypothesis” proposes that brain injury is precipitated by hypoxemia, not trauma.⁴² Other researchers suggest that brain injury is a result of hypoxic injury owing to neural root ganglion damage from neck motion, brain-stem dysfunction, and resultant apnea.⁴³ Such injury cannot be seen on imaging studies but may be identified with careful dissection at autopsy. Neither mechanism accounts for subdural hemorrhage, which is not found in the absence of trauma.⁴⁴

For the purpose of prosecution, the time that an injury was sustained may be critical to identifying a perpetrator. However, the time between the infliction of an injury and the onset of clinical symptoms or presentation is variable or uncertain.^{11,45} In a review of cases of shaking, 14% of perpetrators stated that the child became symptomatic immediately; 21% noted that the child became exhausted immediately, fell asleep, and then showed symptoms 1.5 to 3 hours later; and the remainder were uncertain about the time between the shaking and symptoms, although in all cases the duration was less than 24 hours.¹¹ In general, symptoms or signs of massive intracranial injury, including hemorrhage and cerebral edema, occur in close temporal proximity to the injurious event. A lucid interval — a symptom-free period between injury to the head and subsequent deterioration — may occur with epidural hematoma (and, in rare cases, with subdural hematoma). The duration of the interval is unpredictable and varies depending on the source of the bleeding (arterial or venous) and on the degree of vascular disruption. Although these uncertainties are well recognized in the medical

community, data limitations and inconsistencies pose particular challenges in the courtroom, where greater certainty is expected.

Current efforts to prevent child abuse include home visitation by trained clinical personnel and parenting education, which targets potential precipitating events, such as infant crying (by recommending that parents “carry, comfort, walk and talk” or walk away) and toilet-training accidents (by informing parents of realistic developmental expectations).^{46,47} A 10-year study compared the rate of hospitalization for abusive head trauma among infants 23 months of age or younger in a state that had a universal education program for parents of newborn infants regarding violent infant shaking with the rate in five other states without such a program. The results of the study showed that the program was not associated with a reduction in the rate of hospitalization.⁴⁸

GUIDELINES

Recommendations regarding the evaluation and management of suspected victims of physical child abuse have been published by the American Academy of Pediatrics.^{7,12,15,36} A list of recommended steps to be taken to assess suspected cases of physical child abuse is provided in Table 1. The reporting of cases is not mandated in all

countries. The International Society for the Prevention of Child Abuse and Neglect provides a forum for discussion and exchange of best practices among nations. U.S. guidelines are recognized internationally as a framework for child abuse evaluations. Recommendations in the current article are concordant with U.S. guidelines.

CONCLUSIONS AND RECOMMENDATIONS

The infant in the vignette has had a brief unexplained event that has resolved and has facial bruising, findings that arouse concern for abusive head trauma. The infant should be admitted to the hospital and evaluated with an MRI, a fundoscopic examination for retinal hemorrhages, a skeletal survey, measurement of hepatic and pancreatic enzymes, and coagulation studies. A more extensive social history should be obtained, including who was caring for the infant during the mother's absence and whether other children are in the home (Table 1). The case must be reported to child protective services. All findings should be recorded meticulously in the infant's medical record.

No potential conflict of interest relevant to this article was reported.

Disclosure forms provided by the author are available with the full text of this article at NEJM.org.

REFERENCES

1. Kempe CH, Silverman FN, Steele BF, Droegemueller W, Silver HK. The battered-child syndrome. *JAMA* 1962;181:17-24.
2. Administration for Children and Families, Administration on Children, Youth and Families, Children's Bureau. Child maltreatment 2015 — data tables. Washington, DC: Department of Health and Human Services, 2017 (<http://www.acf.hhs.gov/programs/cb/research-data-technology/statistics-research/child-maltreatment>).
3. Duhaime AC, Gennarelli TA, Thibault LE, Bruce DA, Margulies SS, Wisner R. The shaken baby syndrome: a clinical, pathological, and biomechanical study. *J Neurosurg* 1987;66:409-15.
4. Prange MT, Coats B, Duhaime AC, Margulies SS. Anthropomorphic simulations of falls, shakes, and inflicted impacts in infants. *J Neurosurg* 2003;99:143-50.
5. Jones R, Flaherty EG, Binns HJ, et al. Clinicians' description of factors influencing their reporting of suspected child abuse: report of the Child Abuse Reporting Experience Study Research Group. *Pediatrics* 2008;122:259-66.
6. Ludwig S, Warman M. Shaken baby syndrome: a review of 20 cases. *Ann Emerg Med* 1984;13:104-7.
7. Christian CW, Block R. Abusive head trauma in infants and children. *Pediatrics* 2009;123:1409-11.
8. Ellingson KD, Leventhal JM, Weiss HB. Using hospital discharge data to track inflicted traumatic brain injury. *Am J Prev Med* 2008;34:Suppl:S157-S162.
9. Spies EL, Klevens J. Fatal abusive head trauma among children aged <5 years — United States, 1999–2014. *MMWR Morb Mortal Wkly Rep* 2016;65:505-9.
10. Jenny C, Hymel KP, Ritzen A, Reinert SE, Hay TC. Analysis of missed cases of abusive head trauma. *JAMA* 1999;281:621-6.
11. Adamsbaum C, Grabar S, Mejean N, Rey-Salmon C. Abusive head trauma: judicial admissions highlight violent and repetitive shaking. *Pediatrics* 2010;126:546-55.
12. Kellogg ND, American Academy of Pediatrics Committee on Child Abuse and Neglect. Evaluation of suspected child physical abuse. *Pediatrics* 2007;119:1232-41.
13. Levin AV, Christian CW, Committee on Child Abuse and Neglect, Section on Ophthalmology. The eye examination in the evaluation of child abuse. *Pediatrics* 2010;126:376-80.
14. Greiner MV, Berger RP, Thackeray JD, Lindberg DM. Dedicated retinal examination in children evaluated for physical abuse without radiographically identified traumatic brain injury. *J Pediatr* 2013;163:527-31.
15. Section on Radiology, American Academy of Pediatrics. Diagnostic imaging of child abuse. *Pediatrics* 2009;123:1430-5.
16. Leaman LA, Hennrikus WL, Bresnahan JJ. Erratum to: Identifying non-accidental fractures in children aged <2 years. *J Child Orthop* 2016;10:467.
17. Mehta H, Acharya J, Mohan AL, Tobias ME, LeCompte L, Jeevan D. Minimizing radiation exposure in evaluation of pediatric head trauma: use of rapid MR imaging. *AJNR Am J Neuroradiol* 2016;37:11-8.

18. Smith DH, Meaney DF, Shull WH. Diffuse axonal injury in head trauma. *J Head Trauma Rehabil* 2003;18:307-16.
19. van Rijn RR, Spevak MR. Imaging of neonatal child abuse with an emphasis on abusive head trauma. *Magn Reson Imaging Clin N Am* 2011;19:791-812.
20. Chadwick DL, Bertocci G, Castillo E, et al. Annual risk of death resulting from short falls among young children: less than 1 in 1 million. *Pediatrics* 2008;121:1213-24.
21. Maguire SA, Kemp AM, Lumb RC, Farewell DM. Estimating the probability of abusive head trauma: a pooled analysis. *Pediatrics* 2011;128(3):e550-e564.
22. Hymel KP, Willson DF, Boos SC, et al. Derivation of a clinical prediction rule for pediatric abusive head trauma. *Pediatr Crit Care Med* 2013;14:210-20.
23. Trokel M, Discala C, Terrin NC, Sege RD. Patient and injury characteristics in abusive abdominal injuries. *Pediatr Emerg Care* 2006;22:700-4.
24. Lane WG, Dubowitz H, Langenberg P. Screening for occult abdominal trauma in children with suspected physical abuse. *Pediatrics* 2009;124:1595-602.
25. Gaines BA, Shultz BS, Morrison K, Ford HR. Duodenal injuries in children: beware of child abuse. *J Pediatr Surg* 2004;39:600-2.
26. Lindberg DM, Shapiro RA, Blood EA, Steiner RD, Berger RP. Utility of hepatic transaminases in children with concern for abuse. *Pediatrics* 2013;131:268-75.
27. Maguire S, Mann MK, Sibert J, Kemp A. Are there patterns of bruising in childhood which are diagnostic or suggestive of abuse? A systematic review. *Arch Dis Child* 2005;90:182-6.
28. Sugar NF, Taylor JA, Feldman KW. Bruises in infants and toddlers: those who don't bruise rarely bruise. *Arch Pediatr Adolesc Med* 1999;153:399-403.
29. Sheets LK, Leach ME, Koszewski JJ, Lessmeier AM, Nugent M, Simpson P. Sentinel injuries in infants evaluated for child physical abuse. *Pediatrics* 2013;131:701-7.
30. Maguire S, Hunter B, Hunter L, Sibert J, Mann M, Kemp AM. Diagnosing abuse: a systematic review of torn frenulum and other intra-oral injuries. *Arch Dis Child* 2007;92:1113-7.
31. Maguire S, Mann MK, Sibert J, Kemp A. Can you age bruises accurately in children? A systematic review. *Arch Dis Child* 2005;90:187-9.
32. Duffy SO, Squires J, Fromkin JB, Berger RP. Use of skeletal surveys to evaluate for physical abuse: analysis of 703 consecutive skeletal surveys. *Pediatrics* 2011;127(1):e47-e52.
33. Kemp AM, Dunstan F, Harrison S, et al. Patterns of skeletal fractures in child abuse: systematic review. *BMJ* 2008;337:a1518.
34. Kleinman PK. Problems in the diagnosis of metaphyseal fractures. *Pediatr Radiol* 2008;38:Suppl 3:S388-S394.
35. Barsness KA, Cha ES, Bensard DD, et al. The positive predictive value of rib fractures as an indicator of nonaccidental trauma in children. *J Trauma* 2003;54:1107-10.
36. Jenny C, Committee on Child Abuse and Neglect. Evaluating infants and young children with multiple fractures. *Pediatrics* 2006;118:1299-303.
37. Trivedi DP, Doll R, Khaw KT. Effect of four monthly oral vitamin D3 (cholecalciferol) supplementation on fractures and mortality in men and women living in the community: randomised double blind controlled trial. *BMJ* 2003;326:469-74.
38. Schilling S, Wood JN, Levine MA, Langdon D, Christian CW. Vitamin D status in abused and nonabused children younger than 2 years old with fractures. *Pediatrics* 2011;127:835-41.
39. Perez-Rossello JM, Feldman HA, Kleinman PK, et al. Rachitic changes, demineralization, and fracture risk in healthy infants and toddlers with vitamin D deficiency. *Radiology* 2012;262:234-41.
40. Cheung MS, Glorieux FH. Osteogenesis imperfecta: update on presentation and management. *Rev Endocr Metab Disord* 2008;9:153-60.
41. Committee on Child Abuse and Neglect. Shaken baby syndrome: rotational cranial injuries – technical report. *Pediatrics* 2001;108:206-10.
42. Geddes JF, Vowles GH, Hackshaw AK, Nickols CD, Scott IS, Whitwell HL. Neuropathology of inflicted head injury in children. II. Microscopic brain injury in infants. *Brain* 2001;124:1299-306.
43. Matsches EW, Evan RM, Pinckard JK, Joseph JT, Lew EO. Shaken infants die of neck trauma not of brain trauma. *Acad Forensic Pathol* 2011;1:82-91.
44. Matschke J, Voss J, Obi N, et al. Non-accidental head injury is the most common cause of subdural bleeding in infants <1 year of age. *Pediatrics* 2009;124:1587-94.
45. Bell E, Shouldice M, Levin AV. Abusive head trauma: a perpetrator confesses. *Child Abuse Negl* 2011;35:74-7.
46. Levey EJ, Gelaye B, Bain P, et al. A systematic review of randomized controlled trials of interventions designed to decrease child abuse in high-risk families. *Child Abuse Negl* 2017;65:48-57.
47. Barr RG. Preventing abusive head trauma resulting from a failure of normal interaction between infants and their caregivers. *Proc Natl Acad Sci U S A* 2012;109:Suppl 2:17294-301.
48. Dias MS, Rottmund CM, Cappos KM, et al. Association of postnatal parent education program for abusive head trauma hospitalization rates. *JAMA Pediatrics* 2017;171:223-9.

Copyright © 2017 Massachusetts Medical Society.

NEJM CLINICAL PRACTICE CENTER

Explore a new page designed specifically for practicing clinicians, the NEJM Clinical Practice Center, at NEJM.org/clinical-practice-center. Find practice-changing research, reviews from our Clinical Practice series, a curated collection of clinical cases, and interactive features designed to hone your diagnostic skills.